

Clinical Case Study: aEEG Monitoring on Infant with HIE

Patient Characteristics

A female infant born at 40+3 weeks gestation with a birth weight of 3450 grams. The mother was G2P1 with known hypothyroidism, antibody negative. The pregnancy was uncomplicated and there was spontaneous onset of labour. The amniotic fluid was initially clear when membranes were artificially ruptured, but soon after there was loss of blood. Simultaneously, a deceleration was seen on the CTG. A fetal scalp blood sample showed a pH of 6.84 and an emergency caesarean section was performed. There was no heartbeat, no tone and no spontaneous breathing at birth. After aspiration of blood from her throat, resuscitation was commenced, initially with mask and bag ventilation, followed by intubation after 7 minutes. Chest compressions were started and two doses of adrenalin were given. The first gasp was seen at 15 minutes. Apgar scores were 0, 3 and 5 at 1, 5 and 10 minutes respectively. At the referring hospital 10 ml/kg saline was given and because of hypotension dopamine was commenced (5 microgram/kg/min). Because of the blood loss an erythrocyte transfusion was also given.

The infant was transported to our NICU because of the severe asphyxia and the need for ventilation and hypothermia treatment.

Initial Exam and Clinical Impression

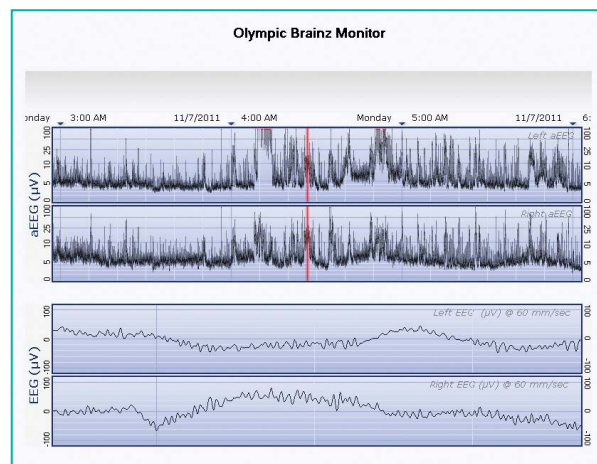
On admission the infant was ventilated with low inspiratory pressure and low concentration of additional oxygen. She developed severe hypotension, and required dopamine (max 15 microgram/kg/min), dobutamine (max 5 microgram/kg/min) and hydrocortisone. Furthermore she developed severe diffuse intravascular coagulation, with ATTP > 120 sec, fibrinogen < 0.1 and D-dimers > 20 mg/L. The infant was given fresh frozen plasma 80 ml/kg, a platelet transfusion of 40 ml/kg and packed cells transfusions of 60 ml/kg. We also administered novoseven (recombinant coagulation factor VIIa).

aEEG Findings

Hypothermia was started around 3.5 hours after birth and from the beginning she showed a severe encephalopathy and a lactate of 16.4 mmol/L 4 hours after birth. aEEG monitoring was started directly after admission which showed a burst suppression pattern with long periods of suppression. Twelve hours after birth the infant developed seizure activity on the aEEG. Phenobarbital 20 mg/kg was given, but seizures persisted, therefore midazolam and lidocaine were given additionally. Following this regime no further seizure discharges were seen. The background pattern did not improve and changed to a more inactive pattern, confirmed by a full EEG.

The infants cranial ultrasound (cUS) initially showed hardly any abnormalities but within 24 hours, echogenicity of the basal ganglia was seen. An MRI on day 4 showed severe abnormalities in the cortex, white matter, basal ganglia and thalami as well. Also abnormalities in the corticospinal tracks were seen and MRS showed a high creatinine and glycine with a normal NAA.

These abnormalities were more extensive than expected for an infant with acute hypoxia and treated with hypothermia. In view of additional problems (severe DIC) and the unknown cause of her perinatal asphyxia, metabolic and genetic disorders were investigated, all of which came back normal.



Outcome

Because of the clinical condition in combination with the almost flat aEEG and the extensive abnormalities seen on MRI a decision was made to withdraw care. Permission for post-mortem examination was obtained. This examination confirmed the extent of the infant's brain injury. It was assumed that the injury occurred around birth. Furthermore, the lungs showed aspiration of amniotic fluid and meconium.

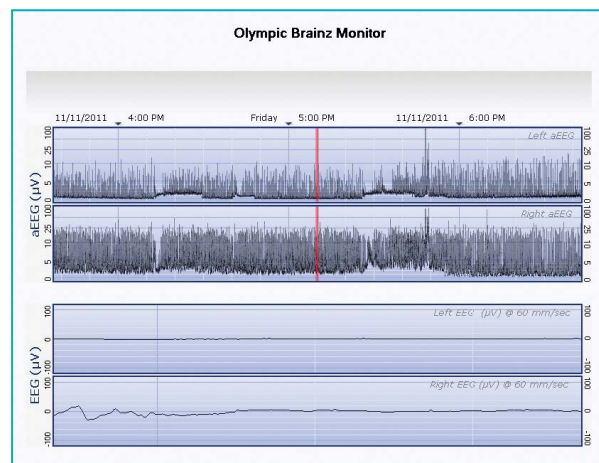
The placenta was also sent to pathology and this examination showed a placenta bilobata with an abnormal insertion of the umbilical cord. This abnormality is likely to be the cause of the severe asphyxia.

Discussion

Hypoxic-ischemic encephalopathy is a severe condition and a common cause of death in term infants. In some cases there is no clear sentinel event which can explain the asphyxia. A thorough examination is of great importance to determine the extent of the injury, caused by the hypoxia-ischemia. To assess the degree of brain injury, aEEG, cranial ultrasound and MRI are essential. In the absence of a sentinel event, additional examinations for underlying metabolic or genetic disorders should be obtained.

Severe abnormalities present on aEEG, cUS and MRI were the reason to redirect care in view of the poor prognosis. When an infant dies, physicians should do their best to obtain permission for post-mortem examination as this will provide additional information to come to a diagnosis.

The last important message from this case is the importance of histologic examination of the placenta. It was this examination which gives the clue in this case.¹



Dr. Linda van Rooij

Department of Neonatology,

Wilhelmina Children's Hospital, Utrecht, The Netherlands

natus

Natus Medical Incorporated
1501 Industrial Road
San Carlos, CA 94070 USA
1-800-303-0306
+1-650-802-0400
www.natus.com

Natus...Where Babies Come First.™

Visit our NERVE Center® education portal at nervecenter.natus.com

¹Harteman JC, Nikkels PG, Benders MJ, Kwee A, Groenendaal F, de Vries LS. Placental pathology in full-term infants with hypoxic-ischemic neonatal encephalopathy and association with magnetic resonance imaging pattern of brain injury. *J Pediatr.* 2013 Oct;163(4):968-95